



Check for updates

**Research Article****Follow-up of *Chrysomya bezziana* Myiasis in a buffalo heifer with notes on larval microscopy, morphology, and taxonomy**Qaisar Jamal¹, Moeen Uddin¹, Israil¹, Mehmood UI Hussan^{1,2}¹ Institute of Zoological Sciences, University of Peshawar, Khyber Pakhtunkhwa, Pakistan.² Government Postgraduate College Nowshera, Khyber Pakhtunkhwa, Pakistan.**ABSTRACT**

This study documents a case of wound myiasis, providing detailed taxonomic and light micrographic data on the causative pest species. The findings highlight critical gaps in livestock healthcare management in rural Khyber Pakhtunkhwa, Pakistan, where farmers often rely on unqualified veterinary practitioners due to limited awareness of proper animal healthcare. In the present case, an unskilled technician administered antibiotic therapy for three days without addressing the myiasis, whereas a qualified veterinarian later confirmed the diagnosis and implemented appropriate treatment. Traditional remedies remain prevalent in the management of animal ailments. Here, a crude 1:1 mixture of Seguvan® (Trichlorfon 98% w/w, Symans Pharmaceuticals, Lahore, Pakistan) and phenolphthalein was applied to eliminate maggots, resulting in rapid expulsion of superficial larvae. However, deeper larvae required mechanical extraction post-mortem. Following maggot removal and necrotic tissue debridement, accelerated wound healing and behavioral recovery were observed. For larval identification, Puri's (gum-chloral) mounting medium proved optimal in clearing morphological features. Key diagnostic characters, including the cephalo-pharyngeal skeleton, intersegmental spines, and anterior and posterior spiracles, were instrumental in confirming *Chrysomya bezziana* as the causative agent. This case underscores the need for improved veterinary care and farmer education to enhance livestock health outcomes in resource-limited settings.

Keywords: *Chrysomya bezziana*; myiasis; buffalo; larvae; taxonomy; cephalopharyngeal skeleton.

**Correspondence**Moeen Uddin
moeenuddin566@gmail.com**Article History**

Received: June 17, 2025

Accepted: August 23, 2025

Published: August 31, 2025



Copyright: © 2025 by the authors.
Licensee: Roots Press, Rawalpindi, Pakistan.

This article is an open access article distributed under the terms and conditions of the Creative Commons Attribution (CC BY) license:
<https://creativecommons.org/licenses/by/4.0>

INTRODUCTION

Myiasis, a parasitic disease of vertebrate animals caused by dipterous larvae, represents a significant global health concern, particularly in tropical and subtropical regions where climatic and socioeconomic factors often worsen its prevalence and intensity (Seugling et al., 2019). The larvae, commonly known as maggots, feed on the host's living or necrotic tissue, body fluids, or ingested food, leading to a wide spectrum of clinical presentations ranging from minor skin irritations to deep, ulcerative wounds and even life-threatening systemic infections (Andriotti et al., 2021). Myiasis has far-reaching public health implications, beyond the direct pathological damage to the host, as certain fly species serve as mechanical carriers for pathogenic microorganisms, increasing the disease burden in affected populations (Fasanella et al., 2010).

Among the various causative agents of myiasis, *Chrysomya bezziana* commonly known as the Old-World screwworm is of peculiar veterinary and medical importance. Unlike facultative myiasis species, *C. bezziana* is an obligate parasite that needs living tissue to complete its larval development, making its infestation, destructive and painful. This species has been reported to cause significant morbidity and economic losses in livestock, companion animals, and, increasingly, in humans

particularly in resource-limited setups. Its aggressive larval invasion can rapidly aggravate superficial wounds, leading to tissue necrosis and systemic complications if not quickly addressed. The species' frequent occurrence in domestic animals such as cattle, buffaloes, sheep, goats, and even pets can underscore its veterinary significance (Pezzi et al., 2020), where it's not only consists of animal welfare but also affects productivity and trade. Dermal myiasis is generally caused by members of three families of flies including, but not limited to, calliphoridae, sarcophagidae and osteridae. Some 21 different species of flies cause myiasis in Indian region. An estimated loss of more than two hundred million dollars is inflicted by myiasis only in Australia (Dar and Mir, 2025). In both endemic and emerging non-native regions the presence of *C. bezziana* poses a growing risk to animal and public health authorities. This species has demonstrated the ability to expand its range into new geographic zones without effective eradication and surveillance measures (Alexander, 2006), aided by increased global trade, climate change, and human mobility. Sterile Insect Technique (SIT) and some other past eradication techniques have shown limited success and are often hindered by the species' geographic plasticity and subtle morphological variations (Wardhana et al., 2012; Andreatta and Bonavina, 2022). In this context, not only for quick clinical intervention but also for epidemiological surveillance and control strategies precise and early identification becomes critical. While the morphological examination of larvae remains a basic diagnostic tool, the use of molecular techniques such as the analysis of internal transcribed spacer 2 (ITS-2) regions provides quality accuracy, especially in distinguishing morphologically similar species at early developmental stages (Chontanarith et al., 2017). Moreover, some *Chrysomya* species, especially including *C. bezziana*, *C. chani*, *C. megacephala*, and *C. villeneuvei*, are vital in forensic entomology, where accurate larval taxonomy can provide critical insights in criminal and medico-legal investigations (Sukontason et al., 2018). Hence, building a comprehensive morphological and molecular database for larval identification remains a high priority.

In the present work, we documented a clinically significant case of wound myiasis in a 3-year-old buffalo heifer caused by *Chrysomya bezziana*. This case not only highlights the destructive potential of the species in livestock but also emphasizes the diagnostic and therapeutic approaches needed for effective management. A detailed account is provided of larval collection, preparation for microscopy, morphological and morphometric analyses, and taxonomic identification underscoring the importance of integrating classical and modern techniques in parasitological research and veterinary practice.

MATERIALS AND METHODS

Case Overview

On 15 August 2017, a 3-year-old female buffalo heifer was found near the University of Peshawar, Peshawar Khyber Pakhtunkhwa, Pakistan with maggot-infested wounds on the flank. The owner had first noticed the lesion two days earlier, on 13 August. The animal had been purchased a month prior and grazed daily in a neglected field containing barbed wire and a stagnant water ditch both potential sources of trauma. Previously, the buffalo had experienced mild diarrhea that resolved without treatment; however, concurrent diarrhea was again noted at the time of myiasis diagnosis.

Clinical Management Timeline

The 28 day follow up of the case is revealed in table 1. The table presents brief history of the signs and symptoms, wound dressing, treatment done and response in terms of animal improvement.

Table 1. Management and treatment history of the case.

Date	Day	Clinical Signs & Observations	Treatment / Intervention	Notes
13 Aug		Wound first observed by owner	None	—
14 Aug	Day 1	Lethargy, wound visible, social withdrawal	20 mL Enrofloxacin IM (Encure-10®)	No wound cleaning done

Date	Day	Clinical Signs & Observations	Treatment / Intervention	Notes
15 Aug	Day 2	Maggots persist, abnormal behavior	10 mL Enrofloxacin IM + 100 mL Sulphasym® IM + 5 Sulf-B boluses (350 mg each, oral)	Behavioral signs unchanged
16 Aug	Day 3	Superficial maggots visible	Topical Seguvan® (98% trichlorfon) + Phenolphthalein (1:1); 5 larvae collected in ethanol	Improvement post-topical application
17 Aug	Day 4	Continued infestation, moderate trauma	Wound debridement by DVM + 15 mL Gentamicin sulfate IM (Genton®)	First surgical intervention
18 Aug	Day 5	Wound cleaning effective, fewer maggots	Irrigation with KMnO ₄ + Seguvan®; 16 dead larvae removed	Clear sign of maggot reduction
19 Aug	Day 6	Secondary trauma due to bird pecking	Antiseptic wound cleansing	No new maggots observed
20 Aug	Day 7	Clinical signs improved; reduced lesion size	Started topical Septran DS® powder (BID)	Parenteral medications discontinued
21–28 Aug	Days 8–14	Epithelialization, cyst resolution, behavior normalized	Continued Septran DS® topically until Day 11	

Taxonomic Analysis of Larvae

A total of 16 larvae were recovered from the wound. Ten larvae were preserved in 70% ethanol and examined microscopically for taking morphometric measurements of taxonomically important morphological and anatomical landmarks. Preparation involved:

- Mounting in Puri's medium after puncturing to release coelomic fluid.
- Separate mounting of anterior and posterior ends for clarity.
- Observation under stereomicroscopy and standard light microscopy.

Morphological Identification

It was based on:

- Key Features: Cephalopharyngeal skeleton, anterior and posterior spiracles.
- Measurements: Landmarks of the cephalopharyngeal skeleton (see Figure. 2A).
- Imaging: High-resolution micrographs captured at multiple magnifications.
- Identification: Cross-referenced with published taxonomic keys for species-level classification.

RESULTS AND DISCUSSION

General Observational Findings

Due to funding difficulties and a lack of professional services, resource-limited farmers commonly turn to illegal veterinary technicians rather than licensed veterinarians, indicating serious gaps in access to veterinary care. For the purpose to prevent additional infections, such professionals often manage the underlying pathology with medication

without treating the initial maggot infestation. According to our clinical observations, effective wound care which included removing maggots, trimming necrotic tissue, and cleaning with antiseptic solution significantly speed up the healing process. Notably, the conventional use of a 1:1 mixture of phenolphthalein and Seguvan® (trichlorfon) showed remarkable effectiveness in killing and driving out maggots without any visible side effects, showing that it could be a reasonably priced intervention in environments with scarce resources. The establishment of standardized techniques needs additional validation through hematologic and serologic tests as well as extensive clinical trials, even though the empirical results were encouraging. This case highlights the urgent need for improved veterinary healthcare infrastructure, enhanced training for para-veterinary workers, and systematic integration of evidence-based practices with traditional knowledge to optimize livestock management in underserved regions.

Table 2. Lesion morphometry.

S. No.	Day	Lesion Perimeter (cm)
1.	3 rd (17/08/2017)	15.35
2.	4 th (18/08/2017)	14.46
3.	5 th (19/08/2017)	12.98
4.	6 th (20/08/2017)	12.38
5.	7 th (21/08/2017)	10.97
6.	8 th (22/08/2017)	9.73
7.	9 th (23/08/2017)	7.78
8.	10 th (24/08/2017)	6.35
9.	11 th (25/08/2017)	5.18
10.	12 th (26/08/2017)	05
11.	13 th (27/08/2017)	04
12.	14 th (28/08/2017)	3.9

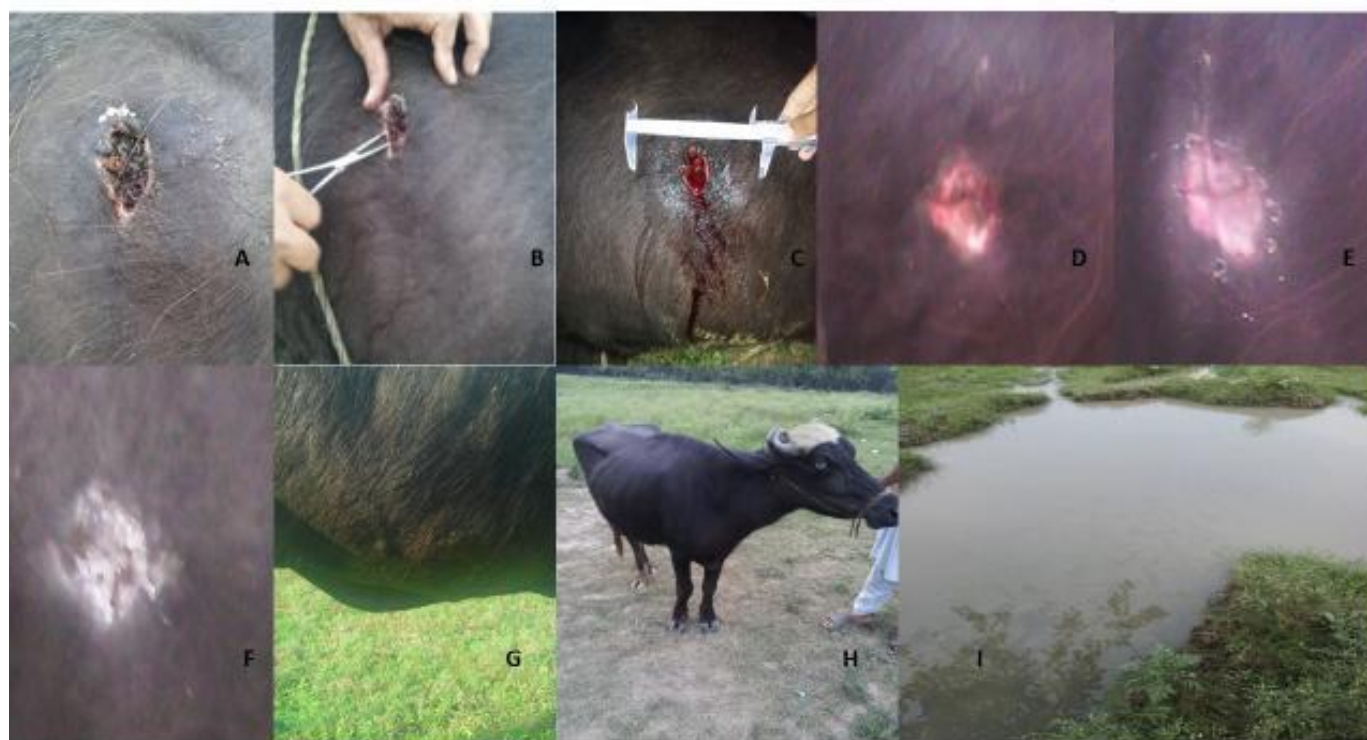

Figure 1. Lesion morphology during treatment and follow-up. Undebrided maggot filled lesion, 16/08/2017 (A), Removal of necrotic tissue, 17/08/17 (B), debrided lesion mouth, 17/08/2017 (C), lesion filled with ground sepran DS powder, 21/08/2017 (D, E), lesion filled with ground sepran DS powder, 24/08/2017 (F), almost healed lesion (G) and animal (H) 28/08/2017, foul water ditch amidst barren land where animal used to sit and drank water from (I).

Morphology and Taxonomy of the Pest Specimen Preparation and Microscopy

Optical microscopy effectively resolved key larval morphological features, including the cephalopharyngeal skeleton (Figure 2), anterior and posterior spiracles, and segmental spines (Figure 3). Among clearing agents, Puri's medium, a gum-chloral-based preparation widely used for sand flies, other insects, and select crustaceans (Upton, 1993; Hazratian et al., 2011; Sayyadi et al., 2013; Poly, 2016; Vahabi et al., 2018), produced optimal tissue transparency, enhancing the visibility of larval structures (Figures 2 and 3). Specimens required approximately one week of post-mounting incubation at room temperature before detailed observation, with extended storage further improving clarity. Notably, mounting dissected larval components yielded superior results compared to whole-larva preparations.

Cephalopharyngeal Skeleton, Spiracles and Spines

Cephalopharyngeal skeleton: The cephalopharyngeal skeleton exhibited robust, dark black cornua with a slight brownish tinge both dorsally and ventrally, though less pronounced than in other species. The distal tip of the ventral cornua displayed a distinct medial indentation, and no discernible fenestral ("window") spot was observed (Figure 2A). Morphometric analysis of key skeletal landmarks (Table 2) revealed high consistency, with minimal individual variation, as indicated by low standard deviations relative to the mean values. These findings suggest that the measured features serve as reliable diagnostic characters for species differentiation.

Table 2. Morphometry of cephalopharyngeal skeleton of 3rd instars (n=10) of *C. bezziana*.

Parameter	Range (mm)	Mean (mm)	Stdev (mm)
Dorsal cornua length	0.48-0.49	0.488	0.005
Ventral cornua length	0.35-0.4	0.3754	0.028
Parastomal bar length	0.124-0.144	0.144	0.001
Vertical plate height	0.28-0.35	0.31	0.031
Dorsal bridge length	0.12-0.144	0.144	0.002
Mouth hook length	0.224-0.256	0.243	0.013
Height at dental Sclerite	0.16-0.256	0.232	0.048
Height at intermediate/pharyngeal sclerite	0.16-0.176	0.166	0.008




Figure 2. Taxonomically significant landmarks and anatomy of the cephalopharyngeal skeleton of the 3rd instar of *C. bezziana*. Lateral view (A), dorso-lateral view (B), and dorsal view (C). ldc=length of dorsal cornua; lvc=length of ventral cornua; ldb=length of dorsal bridge; tl=total length of cephalopharyngeal skeleton; pb=parastomal bar; ds=dental sclerite; hds=height at dental sclerite; ps=pharyngeal sclerite; hps=height at pharyngeal sclerite; hvp=height of vertical plate; lmh=length of mouth hooks.

Anterior Spiracles

The first thoracic segment contains an open spiracular atrium bearing 5–6 (typically 6) papillae. The entire atrial surface exhibits dense dark pigmentation and a granular texture (Figures 2B, 3A, 3B).

Posterior Spiracles

The peritreme is discontinuous, featuring three vertical slits. The main dorsal tracheal trunks exhibit dark pigmentation restricted to a partial segment of the 12th abdominal segment (Figures 3C, 3D). Cuticular spines are single-tipped with broad bases and sharply recurved apices. Dorsally, spines are arranged singly, while ventro laterally on the second thoracic segment, they occur predominantly in triplets, with occasional duplets and quadruplets interspersed (Figures 3E, 3F).

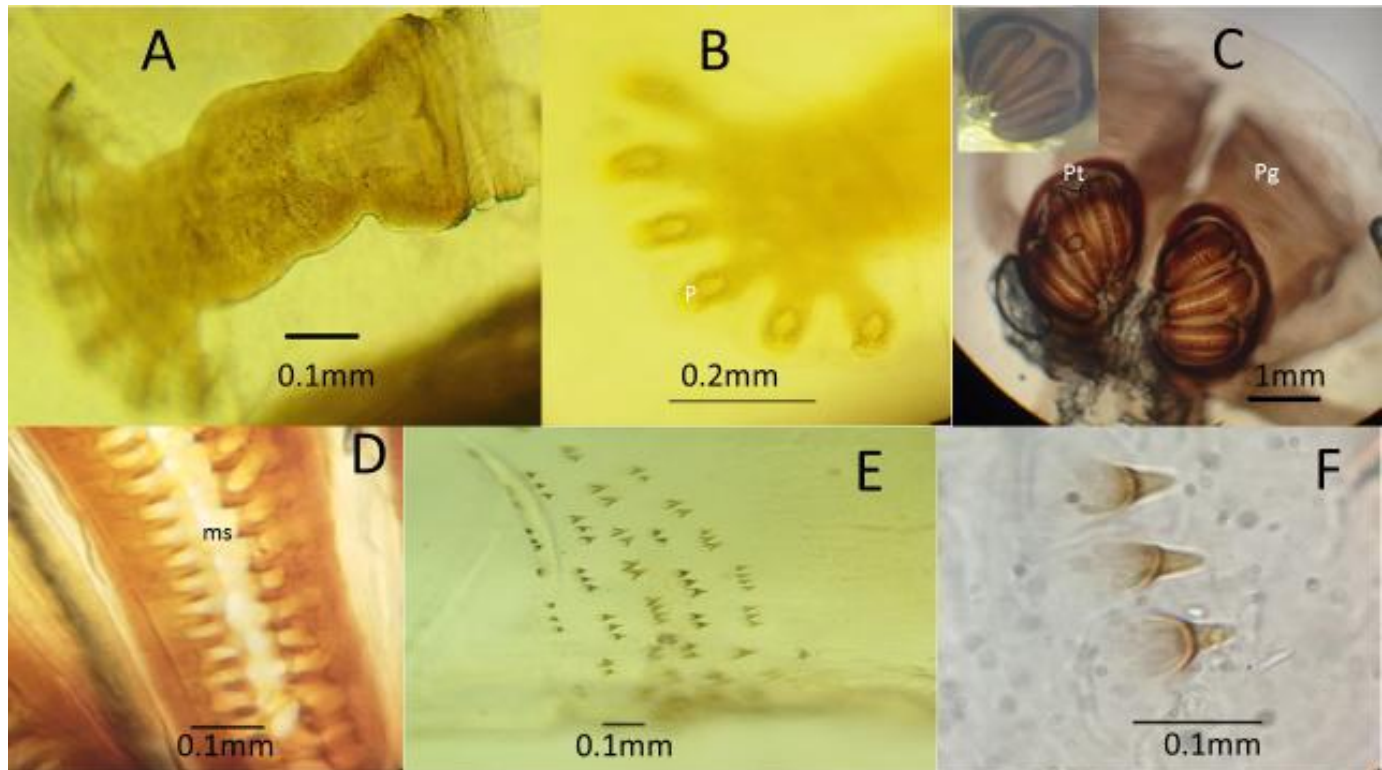


Figure 3. Taxonomically significant anatomical features of anterior and posterior spiracles and spines of the 3rd instar of *C. bezziana*. Anterior spiracle (A, B), posterior spiracle with open peritreme in inset (C), slit of posterior spiracle (D), latero-ventral spines of the 2nd thoracic segment (E), magnified view of the spine triplet with hooded nib pen tip (F); p=papillae or digit of anterior spiracle; pt=peritreme of posterior spiracle; pg= dark pigmented tracheae extending only along 12th segment; ms=median slit.

Effective animal healthcare is still severely limited by the continued prevalence of untrained and poor veterinary practices in both developed and developing nations. Numerous interrelated variables influence this problem, such as low public knowledge, the high expense of professional veterinary care, and the availability and affordability of inexperienced professionals (Nasir, 2016; Staff Reporter, 2015). In many low-income or rural locations, individuals are frequently the primary and only point of care. Unfortunately, this frequently results in ineffective treatment of infections and parasite illnesses like myiasis, raising the possibility of delayed recovery, follow-up infections, and in extreme situations, death.

In the present case, healing was made possible with timely treatment that involved weight-adjusted antibiotic administration, mechanical maggot removal, and antiseptic wound maintenance (using remedies like solution of iodine or turpentine oil). This is in line with earlier treatment guidelines that emphasize the value of evidence-based veterinary care (Rahman et al., 2009). Hydrogen peroxide, iodine, and chlorhexidine diacetate are examples of antiseptics that have demonstrated promise in speeding up the healing process of wounds. However, in environments where untrained practitioners dominate, such results depend significantly on regular follow-up and able clinical oversight components that are frequently absent (Jesse et al., 2016).

Considering this case in an overall epidemiological and forensic aspect is just as important as the therapy aspects. One of the most severe and harmful species that causes wound myiasis in both people and animals is *Chrysomya*

bezziana, the causal agent found in this particular case. Despite other fly species, which are frequently facultative parasites, it is an obligatory parasite. *C. bezziana* has been regularly reported in livestock cases and, progressively, in human myiasis in South Asia, especially in Pakistan (Hassan et al., 2018; Zaidi et al., 2016a, 2016b). This highlights its increasing importance in the area for both veterinary and public health. The presence of *C. bezziana* in Pakistan generates questions about the species' potential as a worldwide pest and its growing range from an epidemiological perspective. Increased global animal exchanges, changes in the climate, and a lack of organized surveillance programs could all lead to its continued expansion. Similar patterns are found when regional research from Bangladesh, India, and Southeast Asia are compared. Due to limited access to diagnostic resources, instances of *C. bezziana* myiasis are frequently underreported, and accurate diagnosis is still insufficient. The development of effective control techniques is restricted by these data gaps. *C. bezziana* has forensic importance in addition to its effects on medicine and veterinary. In forensic studies, accurate species identification especially of larvae can provide essential data about the invasion time and post-mortem durations. The absence of a fenestral ("window") region and the lateral groove at the distal tip of the ventral cornua in third-instar larvae are two morphological features that become particularly significant in this context. As stated by several researchers, such features set *C. bezziana* apart from sympatric species including *C. albiceps*, *C. megacephala*, *C. rufifacies*, and *C. chani* (Queiroz et al., 1997; Sukontason et al., 2018; Zhou et al., 2019). Additionally, the prothoracic and mesothoracic cuticular spine patterns provide essential diagnostic indications that allow better field and lab identifications. The differences seen in *C. bezziana* individuals in this study are in line with earlier findings from Thailand and China when contrasted with regional morphological data on *C. megacephala*, *C. rufifacies*, *C. villeneuvi*, and *C. nigripes* (Sukontason et al., 2005; Zhou et al., 2019). A notable deficiency in local entomological and forensic research is demonstrated by the lack of sufficient morphological data on distributions of these species in Pakistan.

In the end, this case adds to the clinical veterinary literature while offering useful information for forensic entomology and epidemiological mapping in the area in the future. Our incorporation of clinical context and thorough morphological identification highlights the significance of multidisciplinary approaches in the management and comprehension of *C. bezziana* induced myiasis. Reducing the species' impact upon forensic investigations, public health, and animal health will need improving diagnostic capabilities and increasing awareness of the species' wider impact on society.

CONCLUSION

The present study putatively confirms the presence of quackery and inexpert dispensing in veterinary healthcare across rural KP. It also highlights the use of homemade remedies for various veterinary ailments. Light microscopy, if done carefully and by expert hands, is still a gold standard diagnostic tool for myiasis.

AUTHOR'S CONTRIBUTION

QJ conceived the work and carried out the field work; MD worked on the initial draft and data analysis; Israil performed the microscopy and morphometry and refined the manuscript; MH did histological preparation of the maggots for microscopy and helped in the species identification.

FUNDING

The authors did not get any formal funding from anybody. QJ used the lab equipment and chemicals from the regular supplies of the Institute of Zoological Sciences (formerly Department of Zoology), University of Peshawar.

AVAILABILITY OF DATA AND MATERIAL

Not applicable. Whole data available in manuscript.

ETHICS APPROVAL AND CONSENT TO PARTICIPATE

The study was a pilot work and an SOS response to the illness was a need to save the animal taking institutional ethical approval was going to halt the response. A wholehearted consent of the owner was considered enough to proceed. The animal, during the treatment, was handled with great care and any inhumane handling was strictly avoided.

CONSENT FOR PUBLICATION

Not applicable.

CONFLICT OF INTERESTS

Authors have no conflict of Interest regarding this publication.

ACKNOWLEDGEMENT

We are thankful to the Animal's owner for allowing and consenting to work on the animal and providing a detailed history of the animal.

REFERENCES

- Alexander, J. L. (2006). Screwworms. *Journal of the American Veterinary Medical Association*, 228(3), 357–364. <https://doi.org/10.2460/javma.228.3.357>
- Andreato, E. and Bonavina, L. (2022). Wound myiasis in Western Europe: prevalence and risk factors in a changing climate scenario. *European Surgery*, 54: 284-294.
- Andriotti, P. A., Souza, C. P., Oliveira, P. C., Melo, R. C., Verocai, G. G., & Fernandes, J. I. (2021). Effectiveness of sarolaner in the clinical management of furuncular myiasis in dogs naturally infested with *Dermatobia hominis* (Diptera: Cuterebridae). *Parasites & Vectors*, 14(1), 401. <https://doi.org/10.1186/s13071-021-04900-5>
- Chontanarith, T. (2017). Multiplex PCR assay for discrimination of *Centrocestus caninus* and *Stellantchasmus falcatus*. *Asian Pacific Journal of Tropical Biomedicine*, 7(2), 103–106. <https://doi.org/10.1016/j.apjtb.2016.11.020>
- Dar, T. A. and Mir, A. H. (2025). Unravelling the role of Calliphoridae (Insecta: Diptera) as a causative agent of myiasis in sheep with *Chrysomya megacephala* (Fabricius) as the first documented agent of myiasis in ruminants from Kashmir Himalaya, India. *Veterinary Parasitology: Regional Studies and Reports*, 63:101298, <https://doi.org/10.1016/j.vprsr.2025.101298>.
- Fasanella, A., Scasciamacchia, S., Garofolo, G., Giangaspero, A., Tarsitano, E., & Adone, R. (2010). Evaluation of the house fly *Musca domestica* as a mechanical vector for anthrax. *PLOS ONE*, 5(8), e12219. <https://doi.org/10.1371/journal.pone.0012219>
- Hassan, M. I., Khan, M. N., Abubakar, M., Waheed, H. M., & Iqbal, Z. (2018). Prevalence and molecular characterization of *Chrysomya bezziana* (Diptera: Calliphoridae) causing myiasis in livestock in Pakistan. *Veterinary Parasitology*, 253, 30–37. <https://doi.org/10.1016/j.vetpar.2018.02.011>
- Jesse, F. F. A., Sadiq, M. A., Abba, Y., Mohammed, K., Harith, A., Chung, E. L. T., Bitrus, A. A., Lila, M. A. M., Haroon, A. W., & Saharee, A. A. (2016). Clinical management of severe wound myiasis in Brangus-cross calf. *International Journal of Livestock Research*, 6(6), 1–8. <https://doi.org/10.5455/ijlr.20160621012921>
- Nasir, T. (2016, June 18). Quacks invade veterinary medicine practice. *The Guardian Nigeria*. <https://guardian.ng>
- Pezzi, M., Scapoli, C., Chicca, M., Leis, M., Marchetti, M. G., Zingaro, C. N. F. D., Vicentini, C. B., Mamolini, E., Giangaspero, A., & Bonacci, T. (2020). Cutaneous myiasis in cats and dogs: Cases, predisposing conditions, and risk factors. *Veterinary Medicine and Science*, 7(2), 378–384. <https://doi.org/10.1002/vms3.370>
- Poly, W. J. (2016). Collecting and processing Branchiurans. *Journal of Crustacean Biology*, 36(6), 855–859. <https://doi.org/10.1163/1937240X-00002480>
- Queiroz, M. M. C., Moya Borja, G. E., & Queiroz, P. V. (1997). Key for identification of third instar larvae of neotropical calliphoridae (Diptera) of forensic importance. *Memórias do Instituto Oswaldo Cruz*, 92(6), 773–784. <https://doi.org/10.1590/S0074-02761997000600010>
- Rahman, M. A., Hossain, M. A., & Alam, M. R. (2009). Clinical evaluation of different treatment regimes for management of myiasis in cattle. *Bangladesh Journal of Veterinary Medicine*, 7(2), 348–352.
- Sayyadi, M., Vahabi, A., Sayyad, S., Gharib, A., & Vahabi, B. (2013). An entomological survey of phlebotomine sand flies (Diptera: Psychodidae) in Ravansar County, Kermanshah Province, West of Iran. *Life Science Journal*, 10(Suppl. 7), 1–6.
- Seugling, J., Kuhn, S., de Barros, G. P., Velerinho, M. B., Mazzarino, L., & Bricarello, P. A. (2019). Development of *Baccharis dracunculifolia* (Asteraceae) essential oil nanoemulsion and its biological activity on pre-pupae of *Cochliomyia hominivorax* (Diptera: Calliphoridae). *Journal of Pharmacy and Pharmacology*, 7(6), 293–308. <https://doi.org/10.17265/2328-2150/2019.06.003>
- Staff Reporter. (2015, March 15). Officials asked to act against quacks in veterinary medicine. *The Hindu*. <https://www.thehindu.com>
- Sukontason, K., Sukontason, K. L., Piangjai, S., Narongchai, P., Samai, W., Boonchu, N., Sripakdee, D., Ngern-Klun, R., & Siriwattananurongsee, S. (2005). Morphology of second and third instars of *Chrysomya villeneuvei* Patton (Diptera: Calliphoridae), a fly species of forensic importance. *Forensic Science International*, 154(2–3), 195–199. <https://doi.org/10.1016/j.forsciint.2004.10.012>
- Sukontason, K. L., Vogtsberger, R. C., Boonchu, N., Chaiwong, T., Sripakdee, D., Ngern-Klun, R., Piangjai, S., & Sukontason, K. (2005). Larval morphology of *Chrysomya nigripes* (Diptera: Calliphoridae), a fly species of forensic importance. *Journal of Medical Entomology*, 42(3), 233–240. <https://doi.org/10.1093/jmedent/42.3.233>

- Sukontason, K. L., Bhoopat, T., Wannasan, A., Sontigun, N., Sanit, S., Amendt, J., Samerjai, C., & Sukontason, K. (2018). *Chrysomya chani* Kurahashi (Diptera: Calliphoridae), a blow fly species of forensic importance: Morphological characters of the third larval instar and a case report from Thailand. *Forensic Sciences Research*, 3(1), 83–93. <https://doi.org/10.1080/20961790.2018.1428078>
- Upton, M. (1993). Aqueous gum-chloral slide mounting media: A historical review. *Bulletin of Entomological Research*, 83(2), 267–274. <https://doi.org/10.1017/S0007485300034763>
- Vahabi, A., Ahmadian, M., Latifi, S., Mohammadian, A., Ghaderi, Z., Ashrafi, S., & Vahabi, B. (2018). Fauna and the distribution of Phlebotominae sand flies (Diptera: Psychodidae) in Sanandaj County, Kurdistan Province, west of Iran, 2017. *Chronic Diseases Journal*, 6(2), 82–86. <https://doi.org/10.22122/cdj.v6i2.297>
- Wardhana, A. H., Muharsini, S., Ready, P. D., Cameron, M. M., & Hall, M. J. R. (2012). Geographical characteristics of *Chrysomya bezziana* based on external morphology study. *Jurnal Ilmu Ternak dan Veteriner*, 17(3), 177–186.
- Zaidi, F., Ali, N., & Khisroon, M. (2016a). Urinogenital myiasis from blow fly in a Pakistani child. *Journal of the College of Physicians and Surgeons Pakistan*, 26(Suppl. 2), S35–S36. <https://doi.org/10.29271/jcpsp.2016.08.S35>
- Zaidi, F., Fatima, S. H., & Gul, G. (2016b). Dataset of traumatic myiasis observed for three dominant screw worm species in Northwest Pakistan with the first report of *Wohlfahrtia magnifica* (Schiner). *Data in Brief*, 8, 1333–1337. <https://doi.org/10.1016/j.dib.2016.07.053>
- Zhou, X., Kambalame, D. M., Zhou, S., Guo, X., Xia, D., Zhang, Y., & Yang, Y. (2019). Human *Chrysomya bezziana* myiasis: A systematic review. *PLOS Neglected Tropical Diseases*, 13(10), e0007391. <https://doi.org/10.1371/journal.pntd.0007391>